

The Respiratory System

The Respiratory System

The *respiratory system* comprises the air passages (the nose, the cavities of the pharynx, the trachea, the bronchi), and the lungs, together with the ribcage, intercostal muscles, and the diaphragm.

[Figure 6 - 1]

The respiratory system operates by drawing air into the lungs via the air passages. Within the lungs, circulating blood absorbs Oxygen, and gives up Carbon Dioxide, which is passed through the air passages to the atmosphere.

Its primary purpose is to provide a mechanism for the exchange of gases between the outside atmosphere and the blood.

A secondary purpose of the respiratory system is that of voice production and speech.

Additionally, muscles of the respiratory system assist in other body functions.

Air

Air is a mixture of gases, with approximate proportions of:

78% Nitrogen, 21% Oxygen, and 1% Carbon Dioxide and other gases, plus a variable amount of water vapour.

The process of respiration changes these proportions to approximately:
78% Nitrogen, 16% Oxygen, 5% Carbon Dioxide, and 1% other gases. The water vapour saturation level is towards 100%.

Air Passages

Nose

The *nose* is an irregular cavity at the anterior part of the face, with an external protuberance. The nose is divided in two by the *nasal septum* which is composed of cartilage. The floor of the nasal cavity is formed by the roof of the mouth or *hard palate*.

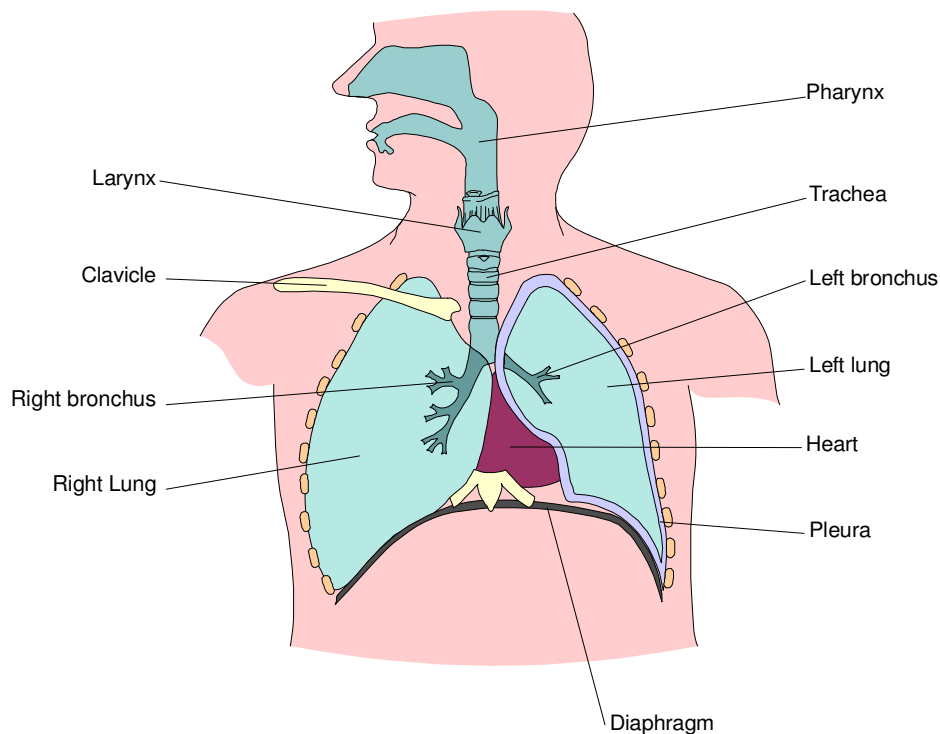
The nasal cavity is lined with ciliated mucous membrane. In the upper part of the nasal cavity, the endings of the olfactory nerve neurones provide the sense of smell.

The irregular internal structure causes turbulence which spreads inhaled air over the surface where mucus absorbs dust and other contaminants, and provides a warming and moistening action.

The nasal cavity opens into the pharynx.

Figure 6 - 1 the respiratory system

A simplified frontal section showing the principal organs of the respiratory system

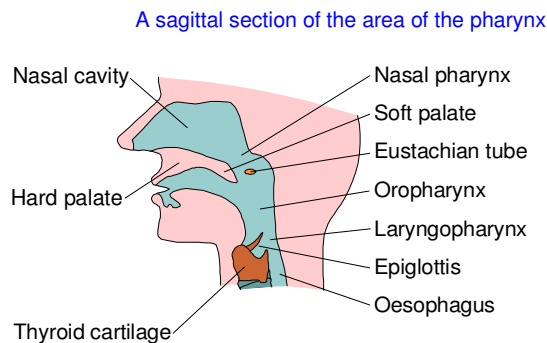


Pharynx

The *pharynx* [Figure 6 - 2] is a cavity lying behind the nose and mouth. Inferiorly, the pharynx opens into the oesophagus and trachea.

The pharynx is divided into three areas: the nasal pharynx, the oropharynx, and the laryngopharynx.

Figure 6 - 2 the pharynx



Nasal pharynx

The *nasal pharynx* is the area immediately superior to the soft palate.

Like the nasal cavity, the nasal pharynx is lined with ciliated mucous membrane.

Auditory tubes (Eustachian tubes) - one from each middle ear - open into the sides of the nasal pharynx.

Oropharynx

The *oropharynx* lies at the posterior part of the mouth, and extends from the soft palate to the epiglottis.

A membranous passageway, known as the *fauces*, separates the oropharynx from the mouth. This passageway opens during swallowing or when inhaling through the mouth.

Laryngopharynx

The *laryngopharynx* is the lowest part of the pharynx and leads into the larynx. At this point the airway and digestive passages divide, the digestive passage continuing as the oesophagus.

Larynx

The *larynx* forms the connection between the pharynx and the trachea. It also contains membranes (the *vocal cords*) which allow the production of sounds.

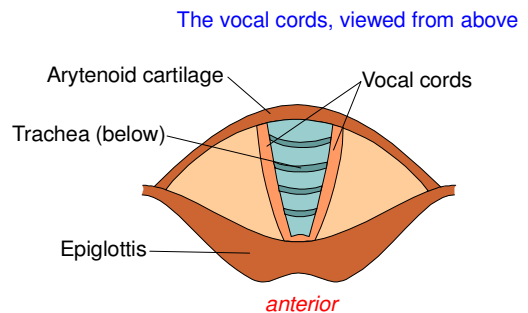
The larynx is supported by the *thyroid cartilage*, the outline of which is visible as the 'Adam's Apple'.

The opening into the larynx is protected by the *epiglottis*. This is a flap of fibrous tissue which moves over the larynx during swallowing so that solids and liquids are directed into the oesophagus.

Vocal cords

The *vocal cords* are made up from two strips of epithelium at the base of the larynx. [Figure 6 - 3]

Figure 6 - 3 the vocal cords



The cords are supported between the *thyroid cartilage* and *arytenoid cartilage*.

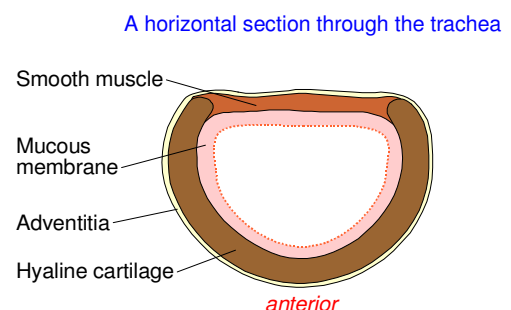
When muscles associated with the arytenoid cartilage contract, the vocal cords are pulled together, leaving only a small gap. In a process termed *phonation*, the vocal cords vibrate and produce sound as air is forced through the gap.

This sound is then formed into the voice by movement of the tongue, mouth, and lips.

Trachea

The *trachea* is a tube which extends from the base of the larynx to the lungs, where it divides into two bronchi. The trachea is formed from connective tissue and smooth muscle, supported by 16 to 20 'C' shaped incomplete rings of cartilage. The cartilage prevents collapse of the trachea, while the open section of the 'C' shape allows dilation and contraction under control of the nervous system, to enhance respiratory effort when necessary.

Figure 6 - 4 the trachea



The trachea [Figure 6 - 4] is formed from three layers of tissue:

Outer layer. This is composed of fibrous and elastic tissue.

Middle layer. This is composed of cartilage and bands of smooth muscle.

Inner layer. This is composed of ciliated mucous membrane.

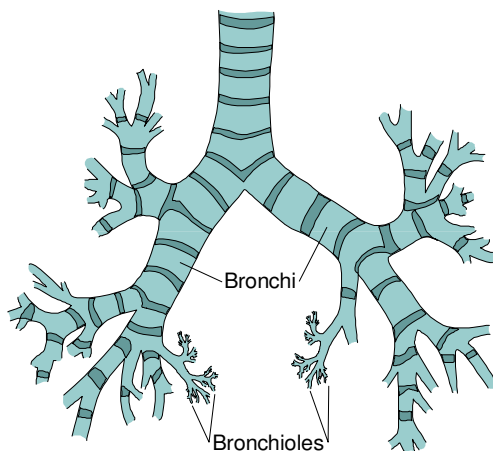
Bronchi and Bronchioles

The *bronchi* are two tubes which originate at the division of the trachea. [Figure 6 - 5]

The left bronchus is slightly longer than the right as it has to pass around the heart to reach the left lung.

Figure 6 - 5 the bronchi and bronchioles

An anterior view showing the basic layout of the bronchi and bronchioles



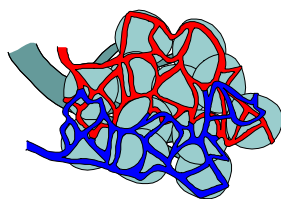
Each bronchus leads into a lung, entering together with the pulmonary blood vessels, at a point known as the *hilum*. Inside the lungs, the bronchi divide, and subdivide, into progressively smaller and more numerous, *bronchioles*.

The bronchi have the same tissue formation as the trachea, allowing similar autonomic nervous control, although the amount of cartilage diminishes towards their distal ends, and is not present in bronchioles.

The bronchioles end in very fine alveolar ducts leading to the alveoli.

Alveoli

The *alveoli*, or air sacs, are the ends of the air passages. They are arranged in bunches, each bunch forming the end of a single bronchiole.



Each alveolus is closely surrounded by blood capillaries so as to allow the exchange of gases to take place between the blood and the inhaled air.

The alveolar walls are composed of a single layer of endothelium - only about 4µm in thickness, allowing the passage of gas, and even individual red blood cells, to and from the surrounding capillaries.

Each lung contains up to 350 million alveoli, giving a total gas exchange surface of approximately 65 m².

Lungs

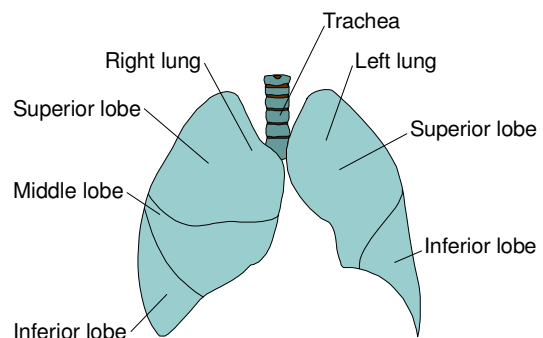
The *lungs*, being the combination of the bronchi, bronchioles, alveoli, and their connecting blood vessels, occupy the majority of the thorax.

[Figure 6 - 6]

The area between the lungs, the *mediastinum*, is occupied by the heart and major vessels.

Figure 6 - 6 the lungs

An anterior view of the lungs



The lungs are subdivided into lobes - the right lung having three: the superior, the middle, the inferior - the smaller left lung having two: the superior, and the inferior. (the left lung is smaller as part of its potential volume is occupied by the heart).

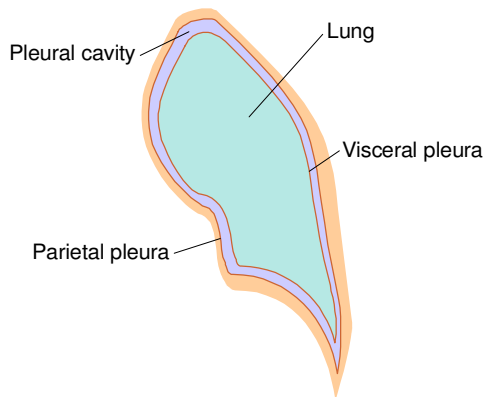
Each lobe is fed by a major division of the appropriate bronchus.

Pleurae

Each lung is enclosed in a membranous sac, or *pleura*. [Figure 6 - 7]

Figure 6 - 7 the pleurae

A frontal section of the left lung illustrating the pleurae
The pleural cavity has been exaggerated for clarity



There are two layers of pleura:

Parietal pleura. This is the outer membrane, which is attached to the inside of the chest wall, and the superior surface of the diaphragm.

Visceral pleura. This is the inner membrane, which is attached to the outer surface of the lung.

The pleurae are composed of serous membrane which secretes fluid into the potential space, the *pleural cavity*, between the parietal and visceral layers. This fluid provides lubrication for the movement which takes place during respiration.

Mechanism of Breathing

Breathing occurs through muscular action, which causes air to move into, or out of, the lungs, by varying the internal pressure in the thorax.

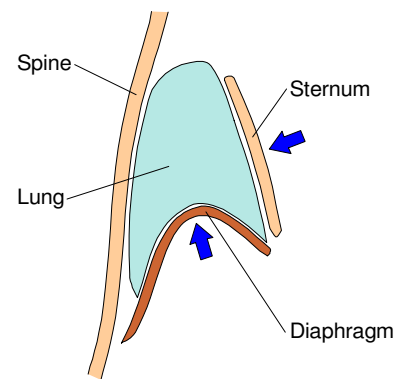
[Figure 6 - 8 and Figure 6 - 9]

Exhalation

Normal *exhalation* (also termed *expiration*) occurs when the muscles of the diaphragm and the external intercostal muscles relax, allowing the thorax to contract under the elastic action of their tissues. The internal pressure is thus raised, forcing air out of the lungs.

Figure 6 - 8 exhalation

The movement of the thorax during exhalation



Forced exhalation (as occurs during exercise) occurs by additional muscular action; internal intercostal muscles contract to pull the ribcage and sternum downwards and inwards. Abdominal muscles press the abdominal organs against the relaxed diaphragm. The abdominal muscular action is stronger than the normal respiratory muscular action, and much assists in causing a forceful expiration of air from the lungs.

Inhalation

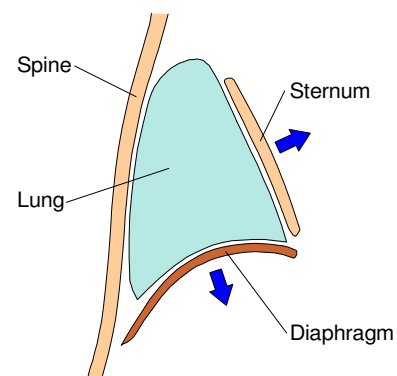
To cause *inhalation* (also termed *inspiration*), the muscles of the diaphragm contract, which causes it to flatten downwards.

Simultaneously, external intercostal muscles contract and cause the rib cage and sternum to move upwards and outwards.

Both these movements increase the volume of the thorax, and lower the internal pressure. Air then flows into the lungs under normal atmospheric pressure.

Figure 6 - 9 inhalation

The movement of the thorax during inhalation



Breath Sounds

Placing a stethoscope against the chest wall over the positions of the lungs will allow the sounds of breathing to be heard.

These sounds occur as air moves into and out of the lungs, and can be useful in diagnosing respiratory problems.

The sounds of normal breathing, known as *vesicular sounds*, are soft and without crackles or whistles.

The sounds may increase or decrease in conditions of injury or illness, particularly if a lung is not inflating properly.

Sounds in addition to normal breath sounds may indicate problems:

Crepitations or rales. These are fine crackles which may indicate fluid or obstruction in the smaller air passages.

Rhonchi. These are 'musical' sounds produced by air passing through narrowed air passages.

Stridor. This is a harsh whistle caused by a partial blockage - often in a major air passage.

Wheeze. This is either a high or a low pitched sound caused when air is forced through narrowed air passages - usually resulting from muscular spasm or mucus.

Transport of Gases

The transport of gas (Oxygen and Carbon Dioxide) to and from the air and the tissues requires two sets of gas exchange - into and out of the blood. These exchanges are known as external respiration and internal respiration.

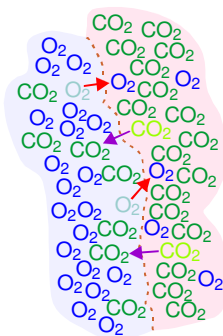
External respiration occurs in the lungs, where blood in the capillaries exchanges gases with the air in the alveoli.

Internal respiration occurs in active tissue, where blood in the capillaries exchanges gases with the tissue cells.

Both sets of gas exchange take place because of differing partial pressures. (*Partial pressure* being the pressure exerted by a gas in a mixture, proportional to the concentration of that gas in the mixture).

In the lungs, the partial pressure of Carbon Dioxide in the blood is higher than that in the air in the alveoli; Carbon Dioxide thus moves into the alveoli.

As the partial pressure of Oxygen is higher in the alveolar air than in the blood, Oxygen moves into the blood.



Within the tissues the partial pressures are 'reversed', the gas movements are thus in the opposite directions.

Transport of Oxygen

Oxygen is transported in the blood as a dissolved gas, but to a much greater extent, in combination with haemoglobin.

Oxygen and haemoglobin form a loose association, which allows the haemoglobin to take on Oxygen in the lungs, but to release it in the tissues.

The binding of Oxygen to haemoglobin is encouraged by a high partial pressure of Oxygen, and the release is encouraged by a high partial pressure of Carbon Dioxide.

Transport of Carbon Dioxide

Carbon Dioxide is transported in the blood as a dissolved gas, as Carbonic acid (formed when Carbon Dioxide and water combine), and in combination with haemoglobin.

As with Oxygen, the binding and release of Carbon Dioxide and haemoglobin are controlled by the relative partial pressures of Oxygen and Carbon Dioxide.

Pulse Oximetry

A *pulse oximeter* is a device which measures the saturation of Oxygen attached to haemoglobin in the blood.

A typical pulse oximeter is based on a 'probe' which passes red and infra-red light through body tissue - most commonly at a fingertip - into light level detectors. Oxygenated haemoglobin and non-Oxygenated haemoglobin absorb red and infra-red light in different proportions, allowing calculation of Oxygen saturation from the detected light levels.

The amount of blood in the tissues varies with the heartbeat, as thus do overall light absorption levels. This allows detection of the pulse as well as permitting calculations to take account of absorption factors of the skin and other tissues.

A pulse oximeter displays SpO_2 - the peripheral Oxygen saturation. In most situations, this is a good indication of SaO_2 - arterial Oxygen saturation.

Pulse oximetry may be used to assess respiratory effectiveness, and can give warning of reduced Oxygen levels prior to other signs developing.

A normal SpO_2 is 95% - 100%.

A level of less than 95% is generally cause for concern, although levels as low as 90% may be the norm for those with chronic pulmonary diseases.

Control of Breathing

Although breathing rate and depth may be temporarily controlled by the conscious will, main control of breathing is maintained by the autonomic nervous system, in response to the body's need for Oxygen.

Autonomic Nervous Control

The respiratory centre in the medulla oblongata in the brain controls the muscles of respiration via the phrenic nerve. The control is spread between two neurone circuits, the inspiratory and expiratory neurones, which trigger alternately to cause inhalation and exhalation.

Additional centres in the pons back up and reinforce the control from the medulla oblongata.

Chemical Control

The acidity of the blood is directly dependent on the concentration of Carbon Dioxide.

A higher blood acidity directly affects the respiratory centre in the brain and leads to an increased respiratory rate.

Sensors

Nerve sensors on the aorta, and on the carotid arteries, also detect the acidity level and initiate an appropriate variation of the breathing rate.

The concentration of Oxygen in the blood has little effect on respiration, with relatively large changes in Oxygen level required to make significant alterations in the respiratory rate.

Respiration is also controlled by sensors in joints and muscles in response to exercise and movement.

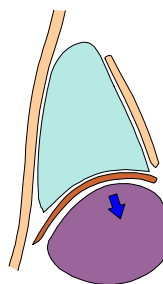
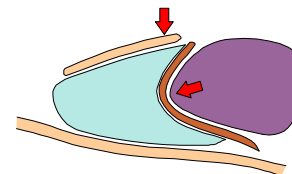
The lungs themselves assist in controlling respiration, as the arterioles and alveoli dilate and contract in response to varying concentrations of Oxygen and Carbon Dioxide.

Sensors in the lungs inhibit further inhalation into alveoli which are stretched by being full, and 'request' inhalation into unstretched alveoli.

Effects of Posture on Respiration

When a person is fully recumbent, gravity forces the abdominal organs against the diaphragm, increasing the force required for it to contract and lower. Gravity also increases the force required to lift the ribcage.

Breathing is thus less easy.



In the semi-recumbent position (or when sitting or standing) gravity aids the lowering of the diaphragm, and has a minimal effect against the expansion of the ribcage. Breathing is thus made easier.

Lung Capacities

[Table 6 - 1]

Normal respiration makes use of only a small proportion of total lung capacity. This leaves a considerable capacity to allow the additional gas exchange required by exertion or exercise. The various volumes of air which are, or which may be, contained within the lungs are defined as:

Resting tidal volume. This is the volume of air inhaled and exhaled in a single breath when at rest.

Inspiratory reserve volume. This is the volume of air, in excess of the resting tidal volume, which may be inhaled in the deepest possible breath.

Expiration reserve volume. This is the volume of air, beyond the resting tidal volume, which may be forcibly exhaled.

Residual volume. This is the volume of air remaining in the lungs after forcible exhalation.

Table 6 - 1 lung capacities

Average lung capacities, in litres, for adults

Volume	Males	Females
Resting tidal	0.5	0.5
Inspirational reserve	3.3	1.9
Expirational reserve	1.0	0.7
Residual	1.2	1.1

Asphyxia

Asphyxia is a general term inferring prevention of normal respiration.

Typical causes of asphyxia include such as drowning, inhalation of poisons, and being in an Oxygen deprived atmosphere, as well as physical blockage of the airway - either internal or external.

Chronic Obstructive Pulmonary Disease

Chronic obstructive pulmonary disease (COPD) - also known as *chronic obstructive airways disease (COAD)* - is a general term covering diseases which affect the respiratory tract, and which are generally long term in nature.

Asthma

Asthma is a condition which often lies dormant, but which is subject to attacks of respiratory distress - sometimes severe.

The condition is similar in nature to an allergy.

An attack may be brought on by ingesting or inhaling the triggering allergen, or by infection.

Stress or emotional disturbance may lower the resistance to the allergen.

An *asthma attack* is characterised by spasms of the smooth muscle of the bronchioles, together with a swelling of their epithelial lining, which much reduce the ability for air to pass into and - more noticeably - out of the alveoli. Lung capacity is reduced, and breathing becomes very difficult.

Bronchitis

Bronchitis is an inflammation of the mucous membrane in the bronchi. It takes two forms - acute and chronic.

The acute form is caused by bacterial infection and tends to follow other respiratory infections. It usually results in a reduction of the lumen of the bronchi and bronchioles, production of heavy clogging mucus with debilitating cough, and respiratory difficulty.

In *chronic bronchitis*, mucus builds up in the lungs, reducing the ability for gas exchange. This leads to a lower blood Oxygen and higher blood Carbon Dioxide. Over time, the body adjusts to the higher Carbon Dioxide level, and the respiratory centre loses full control. Breathing is then triggered solely by a low Oxygen level, rather than a high Carbon Dioxide level. This reliance on a low Oxygen level for respiratory control is known as the *hypoxic drive*. Permanent cyanosis may be present.

Chronic bronchitis may follow acute bronchitis, or may result from long term heavy smoking, or long term exposure to atmospheric pollutants.

Emphysema

The term *emphysema* is generally used to indicate a respiratory disease where degenerative changes occur in the tissue of the bronchioles, alveolar ducts, and alveoli. It literally means 'air in the tissues'.

Emphysema leads to a loss of elasticity and a breakdown of the bronchiole and alveolar walls. The alveoli become less effective, and the loss of elasticity causes entrapment of air within the lungs. Exhalation is thus made much more difficult and may require considerable muscular action.

The condition may be caused by long term heavy smoking, or it may lead on from bronchitis or other respiratory diseases. Emphysema may be aggravated by frequent coughing which damages the air tract walls.

Pneumonia

Pneumonia is an inflammation of the smallest bronchioles and alveoli in one, or both, lungs.

The most common cause is infection - usually bacterial, but also viral. Pneumonia is also a potential complication resulting from a lowered cough reflex through muscle or nerve damage, long term heavy smoking, inhalation of pollutants, or other pulmonary infections or diseases.

The inflammation reduces the ability for gas exchange with a consequent reduction in respiratory effectiveness, together with coughing and breathlessness.

As neutrophils attack the infection, fluid builds up in the alveoli, further complicating the condition.

Common Cold

In illnesses such as the common cold, viruses invade the mucous membranes of the nose and pharynx. If the immune system does not immediately destroy them, the viruses multiply. As lymphocytes attack the viruses, slight tissue oedema results and there is excessive mucus production. These lead to the 'classic' signs and symptoms of such infections.

The *common cold (coryzal, or viral rhinitis)* is a generally mild viral infection affecting the upper respiratory tracts. Usually, the condition causes no more than irritation to the throat and pharynx, a 'runny nose', sneezing, and nasal discomfort, although a slightly elevated temperature and headache may also occur.

Croup

Croup is the term given to several different diseases (including *laryngo tracheo bronchitis*, *laryngismus stridulosus* and *acute laryngitis*) which affect the upper airway in young children of up to four years age.

Croup tends to begin suddenly, often at night. It produces fever, with swelling and congestion of the upper airway leading to respiratory distress and noisy breathing. A barking cough (often likened to a 'seal bark') is a characteristic sign.

Cystic Fibrosis

Cystic fibrosis is an inherited disease affecting the mucous and sweat glands. Thick mucous forms in the lungs, causing respiratory problems and encouraging infection.

The condition also disturbs pancreatic enzyme production and prevents proper absorption of fats, leading to nutritional problems.

Continual treatment is required. Even with this, the expected lifespan is unlikely to exceed 30 years.

Decompression Sickness

Decompression sickness, 'the bends', or *caisson disease*, occurs when the body is moved from an area of high external pressure to an area of lower pressure, such as when a diver surfaces from a deep dive.

A small amount of Nitrogen gas dissolves into the blood from inhaled air. The amount of dissolved Nitrogen is higher for a higher external pressure. During the change to lower external pressure, some Nitrogen will come out of solution. A slow change of pressure will allow this to occur in the lungs, with the Nitrogen being exhaled. A rapid change of pressure, however, will cause Nitrogen to form gas bubbles inside the blood vessels.

This leads to severe pain in the joints, limbs, and abdomen, together with a headache, dizziness and sometimes paralysis.

In extreme cases, the condition may prove fatal.

Drowning

Drowning is a specific cause of asphyxia, resulting from the immersion of the mouth and nose in liquid - usually water - thus preventing the intake of air.

Physiology of drowning

Sudden immersion in cold water and the realisation of danger often causes sharp intakes of breath. As water is taken into the mouth, considerable amounts will be swallowed, reducing buoyancy and compounding the problem.

Initially, water is kept out of the lungs by spasms of the larynx, by the closing the epiglottis, and by repeated swallowing. However, as breathing becomes impossible, hypoxia leads quickly to unconsciousness.

Once consciousness is lost, the larynx relaxes, as does the epiglottis, and water is able to enter the lungs.

Drowning may be classified into one of five categories:

Near drowning. This occurs if the casualty is rescued before the point of apparent death.

Dry drowning. This occurs when water has not entered the lungs.

Fresh water drowning. This occurs when 'fresh' (not salty) water has entered the lungs. The water interferes with the normal mechanism for exchange of gases in the alveoli. The water also upsets the pH value of the blood as it is rapidly absorbed through the walls of the alveoli and from the digestive system. This in turn can lead to imminent cardiac arrest.

Salt water drowning. This occurs when salt water has entered the lungs. The presence of salt in the alveoli draws water from the blood increasing the amount of fluid in the lungs, and increasing the viscosity of the blood. This in turn reduces the heart rate and effectiveness of the circulation, and may lead to cardiac arrest within eight to twelve minutes of rescue.

Secondary drowning. This occurs as a result of water having entered the body. Water in the stomach is absorbed into the bloodstream, disturbing the pH balance of the blood. This may lead to death up to 72 hours after rescue.

Salt water in the lungs can lead to pulmonary oedema (or *shocked lung syndrome*) many hours after immersion.

Additional factors

Drowning is rarely straightforward - other factors may be involved.

Hypothermia. Immersion for any length of time in cold water may well reduce body temperature to the point of hypothermia.

Mammalian diving reflex. This reflex (which is little understood) can allow complete recovery of apparently dead drowning victims - particularly the young - who have been submerged for 30 minutes or even longer.

It occurs on sudden immersion into icy water, face first. The body systems, particularly respiratory, circulatory, and nervous, enter a condition of almost total shutdown, giving a condition of 'suspended animation' and apparent death.

Prolonged immersion collapse. This can occur following rescue of someone who has been immersed in the water for a considerable time, particularly if they have worn a life jacket, which kept them in an 'upright' attitude.

Whilst in the upright position, the water exerts pressure and a massaging effect on the legs. This assists the flow of venous blood from the lower areas of the body.

On rescue, if the casualty is not laid in a horizontal position, the loss of the water pressure, together with the effects of gravity, can lead to fainting or even sudden death, through pooling of blood in the lower areas.

Epiglottitis

Epiglottitis is a dangerous infection of the epiglottis by *Haemophilus influenzae* bacteria.

It mainly affects children of three to seven years of age.

Onset is acute with a high fever, severe pain on swallowing, and a hoarse brassy cough.

Respiratory distress may cause the sufferer to sit upright, leaning forward with the chin thrust out in order to ease breathing.

Haemothorax

A *haemothorax* results when blood escapes into the pleural space from damaged blood vessels. This applies pressure to a lung, and impairs respiration.

Influenza

Influenza is a viral infection of the respiratory system. There are many different strains, leading to a wide variation in signs and symptoms.

The condition usually begins rapidly, with chills, fever, headache, and aches in the back, limbs and joints. As the condition continues, weakness, fatigue, sweating, a dry cough and respiratory difficulties may develop.

Several weeks of fatigue and depression may follow on from recovery of the main infection.

Pleurisy

Pleurisy is a painful inflammation of the pleura, caused usually by infection, although it may lead on from, or accompany, diseases such as pneumonia, tuberculosis, lung tumours, or influenza.

There are two forms of pleurisy:

Dry pleurisy. This is a straightforward inflammation of the pleura.

Wet pleurisy. This is an inflammation of the pleura causing release of fluid into the pleural cavity.

Pneumoconiosis

Pneumoconiosis is the term used for a variety of chronic inflammatory diseases caused by long term inhalation of solid contaminants. Individual diseases tend to be named according to the causing agent:

Silicosis caused by inhaling silica dust.

Anthraxosis caused by inhaling coal dust.

Asbestosis caused by inhaling asbestos dust.

Byssinosis caused by inhaling textile fibres.

Farmer's lung caused by inhaling dust from hay or straw.

Contaminating particles enter the alveoli, where they are ingested by macrophages, but not destroyed. The macrophages then die, releasing the original particles and agents which lead to the growth of fibrous tissue.

This process repeats many times, building up more and more fibrous tissue and eventually reducing the effectiveness of the lungs below that of normal respiratory requirements. Increasing breathlessness and a chronic cough are common symptoms.

Pneumoconiosis may also lead on to pneumonia, tuberculosis, or lung cancer.

Pneumothorax

A *pneumothorax* occurs when air enters the pleural space. This then prevents the correct inflation of the associated lung, and may exert pressure on the heart, leading to serious problems. The air may enter the pleural space either through an abnormal opening in the chest wall, or from a damaged lung (or a combination of both).

Closed pneumothorax. This occurs when the outer chest wall is intact, or where an abnormal opening has been sealed. This may occur through injury, or may occur spontaneously - more commonly in tall, thin, young men.

Open pneumothorax. This occurs when an opening is made in the chest wall. Air may be sucked in through the opening on inhalation, and blown out on exhalation. The accompanying wound is often termed a *sucking wound*.

Tension pneumothorax. This highly dangerous condition is caused when a one-way valve is created by a flap of damaged lung tissue. Air passes into the pleural space on exhalation, but is not drawn from it on inhalation. The air pressure in the pleural space thus builds up, applying increasing pressure to the injured lung, and eventually to the other lung and the heart.

As the air pressure in the pleural space increases, the lung on the affected side may well collapse.

Pulmonary Contusion

Pulmonary contusion often accompanies other serious chest injuries. Physical damage to the lungs allows blood into the interstitial spaces and alveoli, and the basic mechanism of respiratory gas exchange is impeded.

Pulmonary Embolism

A *pulmonary embolism* is a blockage in a pulmonary artery, usually caused by a blood clot - perhaps originating from a 'deep vein thrombosis' in a leg. The condition reduces respiratory effectiveness and may mimic a myocardial infarction, with acute and severe chest pain, and breathlessness.

Pulmonary Oedema

Pulmonary oedema is a condition where fluid enters the alveoli and interstitial spaces from the pulmonary circulation, causing extreme respiratory distress.

A common cause is left ventricular failure as a side effect of a myocardial infarction.

Other causes include hypertension, disease of the mitral or aortic valves, other infections, drowning, or the inhalation of poisons.

Rib Fractures

Rib fractures tend to affect the front of the middle ribs, as these are long, thin, and poorly protected.

A simple rib fracture is rarely a serious injury, as the intercostal muscles retain the position of the fractured bone.

Flail chest

If three or more adjacent ribs are fractured in more than one place, a segment of the ribcage loses its integrity, and a loose section or *flail section* of chest wall will result, although the intercostal muscles may maintain some support for a time.

As it is not connected to the main body of the ribcage, the flail section does not move properly with the muscular action of respiration, but moves to follow differences in air pressure. This leads to *paradoxical movement*, where the flail segment moves inwards during inhalation, and outwards during exhalation.

Tuberculosis

Tuberculosis is an infection by mycobacterium tuberculosis bacteria. The condition most frequently manifests itself in the lungs (*pulmonary tuberculosis* - previously known as *consumption*), although it can affect tissues throughout the body. It is spread in sputum. It is also carried by cattle and spread in unpasturised milk.

Bacteria inhaled into the lungs cause lesions, known as *tubercles*, in the lung tissue. These may spread to nearby lymph nodes. At this stage, the immune system may fight off the infection, or it may lie dormant, to attack at some later time.

The onset of the disease is slow and begins with a cough. Bloodstained sputum, severe fatigue, loss of appetite and weight, fever, and night sweats all then develop and worsen as the disease takes hold.

Untreated tuberculosis is eventually fatal.

