

---

## Chest Injuries

---

Chest injuries are a major cause of death because of their potential effects on respiration and circulation.

All chest injuries require hospital examination to check for complications.

Apart from the more obvious injuries to the ribcage, lungs, and heart, other organs and tissues may be affected by chest injuries. Damage may well occur to the major blood vessels (aorta, venae cavae) or major air vessels (trachea, bronchi), as well as the diaphragm, and other upper abdominal organs. The signs and symptoms of such internal injuries may not be immediately distinguishable, but may present as, for example, hypovolaemic shock, with no other directly identifiable cause.

Treatment always follows similar rules: Airway maintenance and Oxygen; rapid transport to hospital is often required. Careful monitoring is essential, and the possibility of respiratory (and cardiac) arrest must be considered.

Entonox must not be used when there is *any* chance of a pneumothorax, as it will cause the condition to worsen.

Casualties should be positioned such that the *uninjured* side is uppermost and respiratory movement on that side is thus unrestricted.

### Rib fractures

The most common rib fractures affect the front of the middle ribs, as these are long, thin, and poorly protected.

#### Simple

A simple rib fracture is rarely a serious injury, as the intercostal muscles retain the position of the fractured bone.

#### *Signs & symptoms*

- Pain - made worse by respiration or movement.
- Maybe crepitus on respiration or movement.
- Tenderness at the site of the injury.

#### *Treatment*

Perhaps an arm sling, for the arm on the injured side, to help give stability.

Do not discourage full ventilations or coughing.

Do not apply strapping or bandaging to the chest.

#### Flail chest

If three or more adjacent ribs are fractured in more than one place, a segment of the ribcage loses its integrity, and a loose section (flail section) of chest wall will result, although the intercostal muscles may maintain some support for a time.

As it is not connected to the main body of the ribcage, the flail section does not move properly with the muscular action of respiration, but moves to follow differences in air pressure. This leads to paradoxical movement, ie. inwards during inhalation, and outwards during exhalation.

A flail chest is often accompanied by pulmonary contusion.

#### *Signs & symptoms*

- Difficulty in breathing.
- Pain - on respiration or movement.
- Maybe crepitus on respiration or movement.
- Paradoxical movement of the flail section (may be minimal at first).
- Signs & symptoms of hypoxia.

#### *Treatment*

Place the casualty in a sitting or half sitting position, inclined towards their injured side.

Administer high flow-rate 100% Oxygen.

Support the flail segment to prevent 'outward' excursions - by applying an elevation sling to the arm on the injured side, or (in more extreme cases) by strapping the chest with considerable padding over the flail segment.

## Pulmonary contusion

Pulmonary contusion (bruising of the lungs) often accompanies a flail chest condition. Because the damage to the lung(s) allows blood into the interstitial spaces and alveoli, the basic mechanism of respiratory gas exchange is impeded.

Untreated pulmonary contusion may well prove fatal.

In all cases of chest trauma, the possibility of pulmonary contusion must be considered, especially if the level of consciousness is lowered.

### *Signs & symptoms*

These are similar to those of pulmonary oedema:

- Difficulty in breathing.
- Cough, maybe with bloodstained sputum.
- Signs & symptoms of hypoxia.
- As associated with the causing injury.

### *Treatment*

Place the casualty in a sitting or half sitting position, inclined towards their injured side.

Administer high flow-rate 100% Oxygen.

Provide rapid transport to hospital.

## Pneumothorax

A pneumothorax occurs when air enters the pleural space. This then prevents the correct inflation of the lung(s), and may exert pressure on the heart, leading to serious problems. The air may enter the pleural space either through an abnormal opening in the chest wall, or from a damaged lung (or a combination of both).

### **Closed pneumothorax**

A closed pneumothorax is one where the outer chest wall is intact, or where an abnormal opening has been sealed.

It may occur through injury, or may occur spontaneously - more commonly in tall, thin, young men.

### *Signs & symptoms*

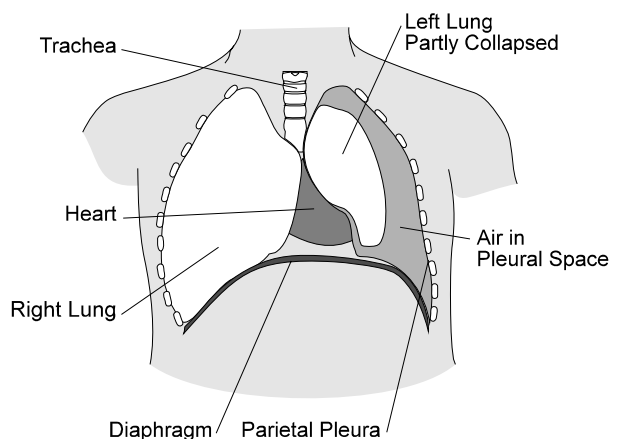
- Chest pain.
- Difficulty in breathing.
- Rapid breathing.
- Reduced chest movement on the injured side.
- Signs & symptoms of hypoxia.

### *Treatment*

Place the casualty in a sitting or half sitting position inclined towards their injured side.

Administer high flow-rate 100% Oxygen.

Provide transport to hospital.



## Open pneumothorax

An open pneumothorax occurs when an opening is made in the chest wall. Air may be sucked in through the opening on inhalation, and blown out on exhalation. The wound is often termed a 'sucking wound'.

### Signs & symptoms

- Pain: in the chest, and at the site of the injury.
- Difficulty in breathing.
- Rapid breathing.
- Reduced chest movement on the injured side.
- Sucking noise as air is drawn through the hole in the chest.
- Cough, maybe with bloodstained sputum.
- Surgical emphysema (air in the tissues) around the wound.
- Signs & symptoms of hypoxia.

### Treatment

Place the casualty in a sitting or half sitting position inclined towards their injured side.

Administer high flow-rate 100% Oxygen.

Seal the wound with an impervious dressing, taped into position (do not create an airtight seal on all four sides of the dressing) Alternatively a 'credit card' may be held in position over the wound.

Transport to hospital.

## Tension pneumothorax

A tension pneumothorax is caused when a 'one way valve' is created by a flap of damaged lung tissue. This causes air to be passed into the pleural space on exhalation, but not to be drawn from it on inhalation. The air pressure in the pleural space thus builds up, applying increasing pressure to the injured lung, and eventually to the other lung and the heart.

Tension pneumothorax is a highly dangerous condition which can prove fatal in a very short time.

### Signs & symptoms

- Pain - chest, and at injury site.
- Difficulty in breathing.
- Rapid breathing.
- A marked reduction, and continued diminution, of chest movement on the injured side.
- Cough, maybe with bloodstained sputum.
- Bulging of intercostal muscles.
- Surgical emphysema.
- Low blood pressure.
- Distension of the veins in the neck.
- Deviation of the trachea away from the injured side (this is a 'late' sign).
- Signs & symptoms of hypoxia.

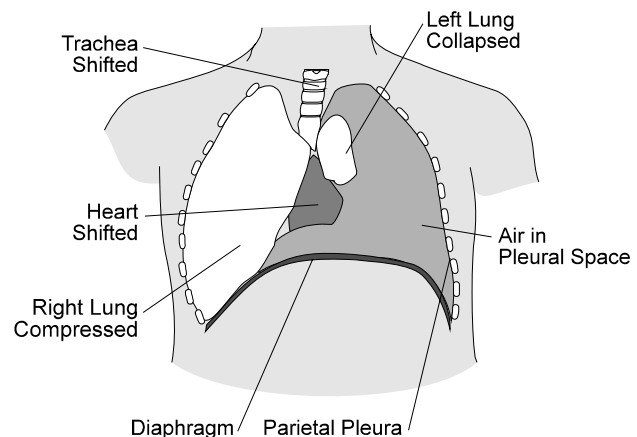
### Treatment

Place the casualty in a sitting or half sitting position, inclined towards their injured side.

Administer high flow-rate 100% Oxygen.

If a sucking wound is present, loosen any sealing dressing to release the build up of pressure.

Provide rapid transport to hospital.



## Haemothorax

A haemothorax is created when blood escapes into the pleural space. Although this applies pressure to a lung, and impairs respiration, the main problems of the condition are those associated with the loss of the blood.

Haemothorax may accompany other forms of chest injury, particularly those causing flail segments or sucking wounds.

### *Signs & symptoms*

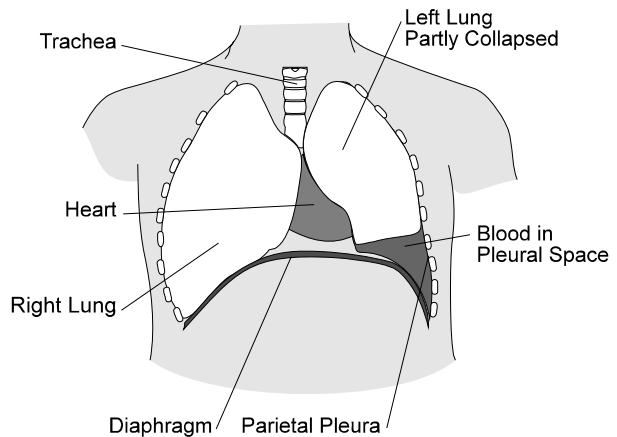
- Difficulty in breathing.
- Rapid breathing.
- Reduced chest movement on the injured side.
- Cough, maybe with bloodstained sputum.
- Signs & symptoms of hypovolaemic shock.
- Signs & symptoms of hypoxia.

### *Treatment*

Place the casualty in a sitting or half sitting position, inclined towards their injured side.

Administer high flow-rate 100% Oxygen.

As required for hypovolaemic shock.



## Traumatic asphyxiation

Traumatic asphyxiation is a misleading term. The condition is the result of an increase in intra-thoracic pressure caused by chest injury. This pressure forces blood out of the right side of the heart into the veins of the chest and neck. The pressure in the capillaries of the head and brain is increased, with the possibility of haemorrhage.

### *Signs & symptoms*

- Cyanosis of the face and neck, but normal colour below.
- Distension of the veins of the neck.
- Bleeding into the eyes.
- As associated with the causing injury.

### *Treatment*

Administer high flow-rate 100% Oxygen.

As required for the injuries present.

## Cardiac tamponade

Cardiac tamponade is a condition caused by fluid in the pericardial space - between the layers of the pericardium.

The condition may occur through bleeding as the result of injury to the heart.

The fluid (blood) in the pericardial space asserts pressure on the heart and reduces its ability to pump and the volume of blood pumped at each beat. The main problems associated with cardiac tamponade are those created by the effects on the circulation.

### *Signs & symptoms*

- Signs and symptoms of cardiogenic shock.
- Distension of the veins of the neck.
- As associated with the causing injury.

### *Treatment*

Administer high flow-rate 100% Oxygen.

As required for cardiogenic shock.

In extreme cases cardiac arrest may occur (maybe with EMD), requiring CPR.